



# Detection of Premaxilla Suprastructure Outline in Edentulous Patients Using Cone Beam Tomography

Ammar Mohi<sup>1</sup>, Shahad Al-Dabbagh<sup>2</sup>, Hamsa K Lafta<sup>2</sup>

<sup>1</sup>*Department of Clinical Dentistry, College of Dentistry, Al-Farahidi University, Baghdad, Iraq, ammar\_19\_80@yahoo.com*

<sup>2</sup>*Department of Prosthodontics, College of Dentistry, Al-Farahidi University, Baghdad, Iraq.*

**Background/purpose:** Residual ridge morphology is an important factor for best rehab performance that is a complex. This clinical chiropractic study using privileges of digital analysis of premaxilla residual ridge (RR) in both partial and complete edentulous patients (PRR/CRR) to differentiate dimensional changes of premaxilla outline and to achieve the relationship between these parameters in both male and female.

**Materials and methods:** forty-five of partial/complete edentulous patient (30 men, 15 women) ranging between 37 and 80 years of age were examined in prosthodontic department. Participants were diagnosed then referred to radiology department for CBCT imaging. By using different linear and ordinal parameters were measured RR of premaxilla Suprastructure with a highly sectional resolution 3D imaging. Spatial analysis correlation regarding surrounding anatomical nasopalatine canal NPC were also used to assess the differences of both sexes PRR/CRR edentulous premaxilla. **Results:** No significant differences in Premaxilla RR segmental levels except in sub-crestal and crestal planes regarding sex or age. Values of the premaxilla height in all CBCT views ranged from 13 mm - 21 mm. Perceived surrounding NCP anatomy was significantly associated with male predilection with complete CRR ( $P < 0.001$ ).

**Conclusion:** A significant association was reported between RR edentulous premaxilla of partial and complete in both gender RR Suprastructure outline particularly sub-crestal and crestal level of RR. Also, a significant association was also observed the surrounding suprastructure figures of NCP. Under the limitation of this study, the evaluation of any future RR complex component will aid in masticatory performance prognostic value for treatment plan of removable denture and/or fixed implants regarding this study.

**Keywords:** Premaxilla, suprastructure outline, masticatory performance, CBCT, high resolution sectional view.

## 1. Introduction

Dentofacial orthopedics complex has a high impact either in success or failure of all esthetics

and functional rehab procedure. Midfacial compartments premaxilla especially has its unique configuration and its crucial influence on this multifactorial serial process. This dimension of the structural complex is highly changeable and depends on factors such as sex, age, and the existence or lack of maxillary anterior teeth <sup>(1-4)</sup>. Surprisingly, due to the significant demands on both aesthetics and functionality, as well as the inadequate quality and amount of residual bone, maxillary anterior rehabilitation has always been a challenging procedure for the doctor <sup>(5-7)</sup>. Prognostic indicators that impact prosthodontic rehab performance PMP include tooth loss, residual ridge, maximal bite force, salivary secretion, tongue and lip function, prior denture experience, and denture stability and retention <sup>(8-11)</sup>. A poor residual ridge (RR) morphology has always a crucial concern for clinicians hoping to achieve successful rehab outcome because CRR/PRR dimensional form are essential to support the denture and prevent dislodgment. It is necessary that a detailed radiographs to obtain a precise anatomical structure to avoid intraoperative complications, such as perforation of the NPC and buccal bone plate <sup>(11,18)</sup>. In clinical practice, conventional 2D radiographs are frequently utilized for preimplant treatment planning; nevertheless, the x-ray beam's projection geometry can cause distortion and two-dimensional images artifacts <sup>(16,17)</sup>. A more precise and in-depth examination of anatomical structures and morphological features, such as the height and form of the residual ridge, has been made possible by advancements in imaging systems and accessible contemporary application of (CBCT) in dentistry. Because of its objectivity, 3D has the potential to be a useful diagnostic clinical impact <sup>(19-25)</sup>.

## **2. Materials and methods**

### **Study Design**

The study was designed as a retrospective study with a medical protocol and ethics of Al-Farahidi university. The scientific ethical review board approved the study (no. 172/2022).

### **Study Sample**

The study sample included CBCT collected up October 2022 of \_April 2024 Dentistry collage of Al-Farahidi university. Forty-fives patients CBCT were screened to use radiologic data of scientific analysis, a specific informed consent form was signed by all patients in this study.

### **Inclusion/Exclusion criteria**

1.patients aged 38 to +60 years; (2) no previous trauma causing surgical treatment or multiple anterior premaxilla teeth extraction; (3) presence of partial or complete edentulous premaxilla (4) FOV of the CBCT image were broad dentoalveolar dimension; (5) high resolution images without any image artifacts; (6) centric occlusion achieved during CBCT acquisition.

2.Patients with history of midfacial trauma, dentofacial malformations or anomaly syndromes, developmental bone diseases, osteometabolic disorders, hormonal diseases were excluded.

### **Data Collection**

The analysis of (DICOM) files allowed to identify and classify both groups of edentulous premaxillae according to Juodzbalys and Daugela (Table.1).

CBCT images were obtained using CBCT device bondent 3D (FOV 15 × 15; 50–100 kVp; 1–  
*Nanotechnology Perceptions* Vol. 20 No.S2 (2024)

22 mA; 200  $\mu$ ) (Vatech, Fort Lee, NJ, USA). According to the analysis of anatomical and radiological principles allowed to evaluate premaxilla bone morphology and NP spatial position accurately.

For each parameter, A vertical height levels, diameter of premaxilla from basal bone and crestal bone in both complete or partial edentulous cases were observed and measured. Two investigators (AM and SA) separately conducted the overall measurements. Any disagreements between the two authors were discussed and judged by a third expert author (AG).

The strategic analysis of the premaxilla was processed by DICOM files segmentation using (On demand Software, Materialise, Technologielaan, Leuven, Belgium) to obtain the dimensional analysis segmentation and the volumetric reconstruction of the premaxilla. This study intraoperative (OMF Radiologist) calibrated researcher (AM) recorded the following measurements:

(1) Levels between basal and crestal bone of premaxilla in sagittal and coronal views were defined diameters of four planes: A (Base), B, C, D (Crest)) (Figure 1).

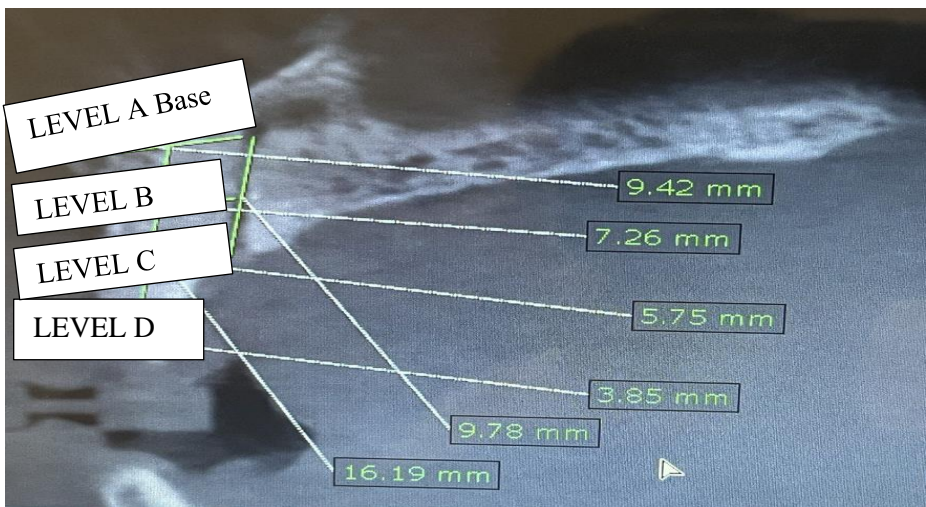


Figure1: Descriptive analysis of Premaxilla levels in sagittal view of CBCT

(2) Linear height and diameters of both premaxilla bone and surrounding NP canal that represented as L SA, L CO, L CP, D SA, D SOP, D SEX were defined by two points: OP and EX and height between these two planes)(Figure2)..

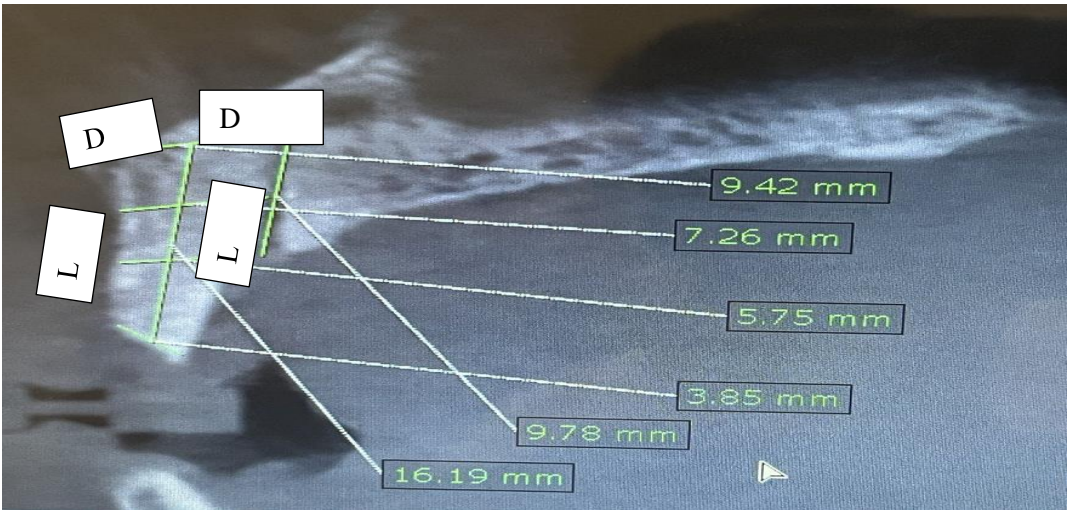


Figure2: Linear analysis of Premaxilla outline in sagittal view of CBCT

This present explorative study aimed to investigate premaxilla residual ridge morphology in relation to CRR/PRR group in both sexes and subsequent prosthodontics therapy. In stage I of study (Part I) investigates the relationship of the spatial geometrical measures of height, diameter at different segmental view sections of the Premaxilla RR (denture base surface area).In stage II of study (part II) analyzes different types and forms of RR the Premaxilla in both PRR/CRRs of the both sex participants were transformed to evaluate the prognostic value of these residual ridge morphology by measuring variables and perceived in future the effectiveness of therapy <sup>(17)</sup>.In stage III of study (part III) correlate a highly significant values between two different groups of CRR/PRR edentulous premaxilla for both males and females then how its positively affect the general outline of RRM in this unique morphology.

3. Results

The study sample included 45 patients (15 women and 30 men) with edentulous anterior premaxilla for both partially and complete maxilla ridge (RR). In Table 1. The mean ratio of 2 to 1 female-to-male provides the total number of males and females included in the study.

Table 1: Descriptive analysis of study groups

Parameters	Type	N (%)
Gender	Male	30 (66.7%)
	Female	15 (33.3%)
Groups	C	35 (77.8%)
	P	10 (22.2%)
Typ S Cr	flat	20 (44.4%)
	flattap	20 (44.4%)

Timing 1/2	tapered	5 (11.1%)
	Yes	35 (77.8%)
	No	10 (22.2%)

The complete denture wearer cases were more than the partial cases. Also, the number of tapered shaped RR in crestal area was lowest than the other flat crest types. The highest percentage of RR outline types in this study was reported in rectangular shape outline with 2:1 ratio, whereas the lowest percentage belongs to the triangle anterior zone. Thirty patients were NPC shape type of V configuration with T shape type outline in lower extent in other half percentages.

Table 2: Descriptive analysis of sagittal premaxilla outline in both sexes

Levels	Gender	N	Mean $\pm$ S.D.	P value
Level A	Male	30	13.22 $\pm$ 1.45	0.002**
	Female	15	11.09 $\pm$ 2.13	
Level B	Male	30	8.14 $\pm$ 1.48	0.728
	Female	15	7.99 $\pm$ 1.27	
Level C	Male	30	5.70 $\pm$ 1.19	0.005**
	Female	15	4.83 $\pm$ 0.74	
Level D	Male	30	3.33 $\pm$ 1.23	0.119
	Female	15	2.81 $\pm$ 0.90	

The included patients were classified into two groups of analysis basically as Partial and complete according to RR denture wearer cases that reported as in Tab.2 For both male and female, A highly significant value appear to be high in middle plane (Level C) represents a nearer level to the crestal plane (Level D) with 5.70-4.83 mm as highly significant value ( $P < 0.005^{**}$ ) Table.2 general descriptive statistics for both sexes included cases. Also, the descriptive analysis showed a nearer mean value of level C width in both partial and complete denture wearer represented the cut-off middle plane for the high-basal and the low-crestal level groups of 5.69-4.43 mm with highly significant statistically ( $P < 0.001^{**}$ ).

Table 3: Descriptive analysis of sagittal premaxilla outline in both groups

Levels	Groups	N	Mean $\pm$ S.D.	P value
Level A	C	35	12.48 $\pm$ 2.11	0.818
	P	10	12.64 $\pm$ 1.42	
Level B	C	35	8.27 $\pm$ 1.00	0.113
	P	10	7.46 $\pm$ 2.31	

Level C	C	35	5.69 ± 1.13	0.001**
	P	10	4.43 ± 0.27	
Level D	C	35	3.10 ± 1.27	0.551
	P	10	3.35 ± 0.51	

Table 4: Descriptive correlation of sagittal premaxilla outline in both sexes and groups .

Groups		Gender	N	Mean ± S.D.	P value
C	Level A	Male	25	13.61±1.27	0.000**
		Female	10	9.66±0.37	
	Level B	Male	25	8.71±0.8	0.000**
		Female	10	7.18±0.46	
	Level C	Male	25	5.97±1.13	0.012*
		Female	10	5±0.86	
	Level D	Male	25	3.26±1.34	0.224
		Female	10	2.72±1.07	
P	Level A	Male	5	11.32±0.26	0.000**
		Female	5	13.97±0.38	
	Level B	Male	5	5.32±0.41	0.000**
		Female	5	9.62±0.55	
	Level C	Male	5	4.36±0.28	0.427
		Female	5	4.51±0.28	
	Level D	Male	5	3.7±0.29	0.023*
		Female	5	3.01±0.44	

A linear standards parameters used for more accurate analysis of RR outline. All cases statistically analyzed for both sexes as appeared in Tab.5.

Table 5: Descriptive analysis of both sexes mean values

Gender		L SA	L CO	L NP	D SOP	D SEX	D COP	D CEK	D AX	
Male	N	Valid	30	30	30	30	30	30	30	
		Missing	0	0	0	0	0	0	0	
	Mean		18.6813	13.3070	15.1840	3.3263	4.3450	4.1713	4.6917	4.2827
	Std. Error of Mean		.89319	.69199	.62343	.18381	.26470	.14128	.20714	.16143
	Median		18.6850	13.3800	15.3450	3.0000	4.3800	4.1700	4.6500	4.0200
	Std. Deviation		4.89221	3.79019	3.41467	1.00675	1.44981	.77380	1.13453	.88416
	Variance		23.934	14.366	11.660	1.014	2.102	.599	1.287	.782



Female	Range	14.38	12.61	11.19	2.84	5.88	2.75	3.69	2.73
	Minimum	12.15	7.36	10.04	2.00	2.02	3.09	3.12	3.17
	Maximum	26.53	19.97	21.23	4.84	7.90	5.84	6.81	5.90
	N	Valid	15	15	15	15	15	15	15
		Missing	0	0	0	0	0	0	0
	Mean	17.4980	5.7440	10.3080	2.5627	4.1380	2.8600	4.7453	4.4967
	Std. Error of Mean	.08289	.30983	.18586	.25209	.48533	.16179	.24030	.56791
	Median	17.4600	5.5600	10.3800	2.9900	3.6900	2.8800	5.1800	3.3000
	Std. Deviation	.32103	1.19997	.71981	.97632	1.87968	.62662	.93068	2.19952
	Variance	.103	1.440	.518	.953	3.533	.393	.866	4.838
	Range	.98	3.18	2.41	2.60	5.40	1.82	2.59	5.63
	Minimum	17.00	4.21	9.17	1.04	2.05	2.05	3.09	2.08
	Maximum	17.98	7.39	11.58	3.64	7.45	3.87	5.68	7.71

A comparison between different linear analysis either in both sexes or both groups of partial and complete denture wearers were estimated significantly. As appeared, in Tab.6 the coronal length and diameter of RR significantly variables differences LCO, LNP and diameter DCOP between 13.31 mm in male rather than 5.74 mm in females. Furthermore, RR diameter was highly significant also between 10.31 to 3.33 mm for male to female analysis.Both partial and complete denture wearer compared together in the same linear parameters to reveal a highly significant difference of more parameters especially in diameters of RR like the L SA, D SEX and diameter D COP and others with highly significant values (P < 0.005).

Table 6: Descriptive analysis of different parameters in both sexes

Parameters	Gender	N	Mean	P value
L SA	Male	30	18.68± 4.89	0.357
	Female	15	17.5± 0.32	
L CO	Male	30	13.31± 3.79	0.000**
	Female	15	5.74± 1.2	
L NP	Male	30	15.18± 3.41	0.000**
	Female	15	10.31± 0.72	
D SOP	Male	30	3.33± 1.01	0.021*
	Female	15	2.56± 0.98	

D SEX	Male	30	4.35± 1.45	0.712
	Female	15	4.14± 1.88	
D COP	Male	30	4.17± 0.77	0.000**
	Female	15	2.86± 0.63	
D CEK	Male	30	4.69± 1.13	0.867
	Female	15	4.75± 0.93	
D AX	Male	30	4.28± 0.88	0.722
	Female	15	4.5± 2.2	

Table 7: Descriptive analysis of different parameters in both groups

	Groups	N	Mean ± S.D.	P value
L SA	C	35	17.74 ± 4.21	0.035*
	P	10	20.19 ± 2.62	
L CO	C	35	10.99 ± 4.84	0.595
	P	10	10.06 ± 4.76	
L NP	C	35	13.39 ± 3.65	0.576
	P	10	14.15 ± 3.73	
D SOP	C	35	3.13 ± 1.14	0.358
	P	10	2.87 ± 0.64	
D SEX	C	35	3.85 ± 1.48	0.000**
	P	10	5.75 ± 0.98	
D COP	C	35	3.52 ± 0.84	0.015*
	P	10	4.49 ± 0.99	
D CEK	C	35	4.34 ± 0.84	0.000**
	P	10	5.99 ± 0.69	
D AX	C	35	3.77 ± 0.89	0.000**
	P	10	6.39 ± 1.11	

Table 8: Descriptive analysis of both sexes correlation with both groups

Groups		Gender	N	Mean ± S.D.	P value
C	L SA	Male	25	17.89 ± 5	0.622
		Female	10	17.39 ± 0.27	
	L CO	Male	25	13.05 ± 4.12	0.000**



P	L NP	Female	10	5.84 ± 1.47	0.000**
		Male	25	14.69 ± 3.53	
	D SOP	Female	10	10.13 ± 0.76	0.001**
		Male	25	3.53 ± 0.98	
	D SEX	Female	10	2.14 ± 0.92	0.017*
		Male	25	4.22 ± 1.55	
	D COP	Female	10	2.93 ± 0.73	0.000**
		Male	25	3.93 ± 0.59	
	D CEK	Female	10	2.49 ± 0.33	0.767
		Male	25	4.31 ± 0.8	
	D AX	Female	10	4.07 ± 0.8	0.001**
		Male	25	3.04 ± 0.66	
	L SA	Female	5	22.66 ± 0.33	0.000**
		Male	5	17.72 ± 0.32	
	L CO	Female	5	14.57 ± 0.28	0.000**
		Male	5	5.55 ± 0.29	
	L NP	Female	5	17.64 ± 0.76	0.000**
		Male	5	10.66 ± 0.53	
	D SOP	Female	5	2.33 ± 0.29	0.000**
		Male	5	3.41 ± 0.3	
	D SEX	Female	5	4.96 ± 0.55	0.002**
		Male	5	6.55 ± 0.52	
	D COP	Female	5	5.38 ± 0.31	0.000**
		Male	5	3.6 ± 0.35	
	D CEK	Female	5	6.59 ± 0.34	0.000**
		Male	5	5.4 ± 0.28	
	D AX	Female	5	5.37 ± 0.3	0.000**
		Male	5	7.41 ± 0.24	

As above mentioned, result reported in Table.8 the descriptive statistics comparison of all groups in relation to male-female analysis. Almost of RR analysis variable appeared to be highly significant for both sexes more than complete denture wearer that some variable not significantly available such as L SA and D CEK that are mostly dependent measurement in clinical assessments. Finally, as level C near the crestal plane of the RR appeared highly significant affected in both sexes and groups, The table 9 shows that male complete wearer group were higher in length and diameters more than other groups and sexes. It also shows that the female partial wearer was more affected by length and diameter which was higher in the analysis protocol compared to the other groups.Immediate-term success reported in this study for all cases was clearly estimated in Figure.3 crystallization plot. There was no statistically significant difference (Chi-Square Test) in the other level between both groups and sexes. The study results showed that only 2 cases needed standards protocols that male complete denture wearer and female partial wearer in the RR analysis protocol, whereas other cases in the conventional sequential measurements appeared not highly affected. This has been statistically confirmed. All Test tables showed a highly significant difference ( $P < 0.001$ ) between both sexes and groups (figure 4,5). These cases were more relevant treated either with *Nanotechnology Perceptions* Vol. 20 No.S2 (2024)

the sequential prosthodontics conventional protocol or surgical GBR plus implants of RR augmented analysis using contemporary digital techniques.

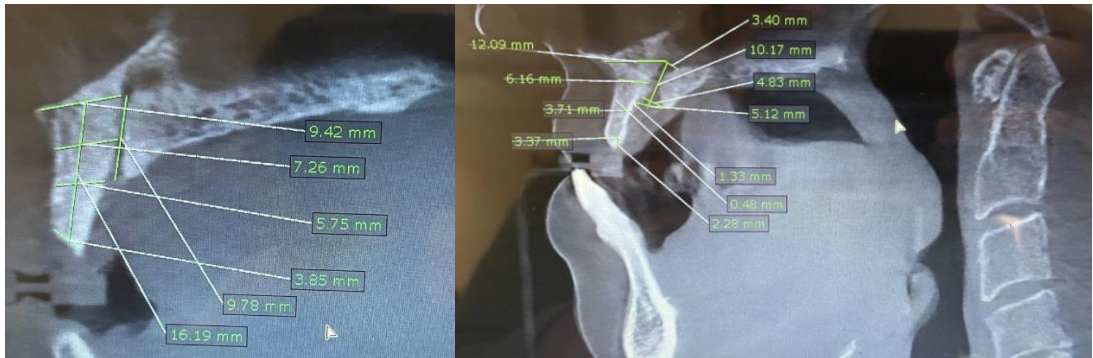


Figure3: a: Linear analysis of Premaxilla outline in sagittal view of CBCT a) CRR outline b) PRR outline

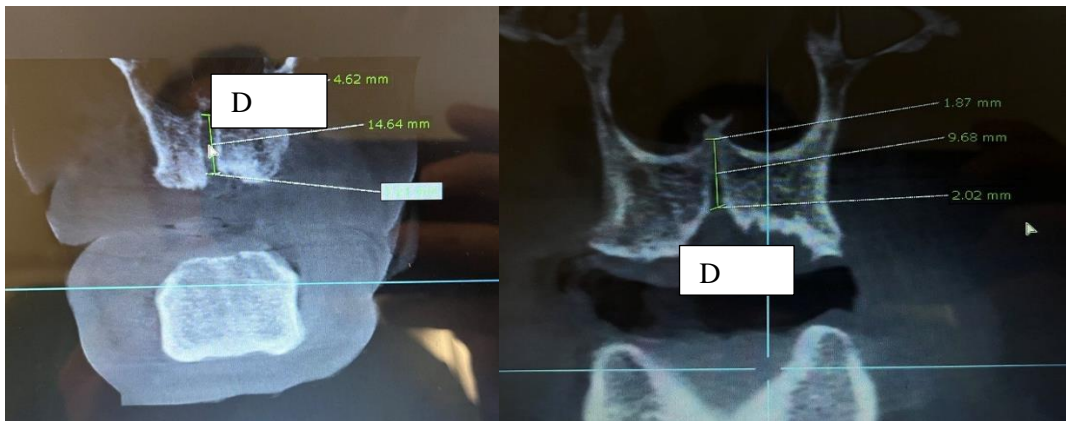


Figure 4 :a/b: Linear analysis of Premaxilla outline in coronal view of CBCT

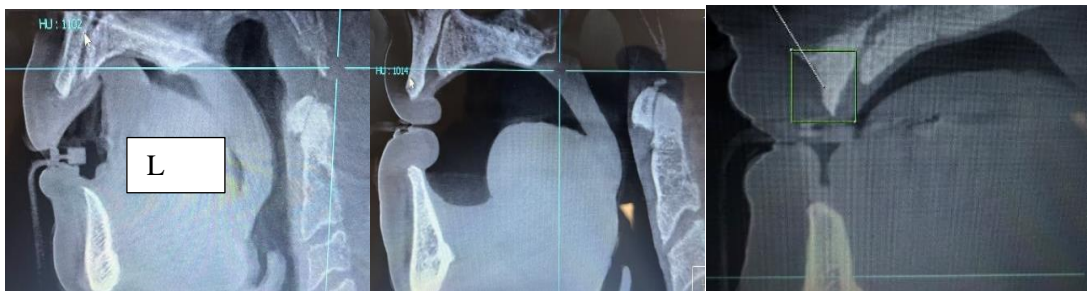

Figure5: Descriptive analysis of Premaxilla crest outline in sagittal view of CBCT  
a) Flat b) Flattap c) Tapered

Table 9 : Significant analysis and correlation of both sexes and both groups edentulism

Gender	Male				Female			
Groups	Group C		Group P		Group C		Group P	
Pearson Correlation	R	P	R	P	R	P	R	P
L SA	.550**	0.004	-0.024	0.97	-0.098	0.787	-0.661	0.224
L CO	.541**	0.005	-0.593	0.292	.669*	0.034	-0.182	0.769
L NP	.491*	0.013	0.727	0.164	0.632	0.05	-0.487	0.405
D SOP	0.146	0.485	0.468	0.427	-.733*	0.016	0.222	0.719
D SEX	.538**	0.006	-0.572	0.313	-0.546	0.102	-0.677	0.209
D COP	-.678**	<0.001	0.588	0.297	-0.54	0.107	.911*	0.031
D CEK	.473*	0.017	-0.711	0.178	.676*	0.032	0.714	0.175
D AX	-0.169	0.419	-0.653	0.232	-0.496	0.144	-0.215	0.729

4. Discussion

The maintenance of underlying RR contour of the premaxilla achieved optimal planning for both functional and aesthetic rehabilitation outcomes, radiographic orthopedic examination of the dentofacial regions—particularly the anterior maxillary zone and mid face complex—is thought to be essential <sup>(2,12,13)</sup>. CBCT has demonstrated excellent accuracy in determining maxillary thickness and height. Furthermore, improved diagnostic efficacy. In addition, these benefits come with less radiation exposure, easy handling, and more accessibility as compared to traditionalCT<sup>(5,19,20)</sup>. It is crucial to identify the nasopalatine canal precisely to prevent harm to its neurovascular contents. By using CBCT, one can prevent complications such as nerve or vascular injury that arise from invasion of the canal.<sup>24</sup> In this case, paresthesia, dysesthesia, anesthesia, or even worse, neuropathic pain, can be the outcome of nerve injury. In turn, vascular issues often show up as excessive bleeding, which normally raises a great deal of alarm even though it is not life-threatening <sup>(20, 22)</sup>. Numerous morphological variations of the nasopalatine canal have been reported; the most widely applied classification schemes are those created by Mardinger and colleagues and Mrwia and colleagues.as well as Liang and associates <sup>(24)</sup>. at least two apertures or auxiliary foramina. When partially edentulous individuals (44 men and 56 women) were referred to the Department of Stomatology and Oral Surgery at the University of Bern (Switzerland) for the implantation of dental implants, Mardinger and colleagues assessed the morphology of the nasopalatine canal. According to previous authors, A nasopalatine canal was observed clearly as one canal then, followed by Y-shaped figure with two separated canals. In this study observed cases, a Y-shaped canal in 64 cases (52.45%) similar to de Oliveira-Santos and colleagues <sup>(8)</sup> that their reported cases of additional foramina were closely adjacent to the incisor canal. According to CBCT results

from several research, the average canal length is between 8 and 12 mm.<sup>4,9</sup> These numbers are consistent with our own data, which show a mean length of 11.02 ± 2.4 mm. On the other hand, a range of 1.1 to 6.7 mm in canal length was recorded by Song and colleagues<sup>(3)</sup>. Our findings are in line with those reported by Liang and associates, who looked at 120 CT scans and 163 dry skulls with a mean canal length of 9.9 mm and a mean canal diameter of 3.3 mm. Tözüm et al. evaluated the canal's length, width, and shape in addition to the width, thickness, and length of the bone between the anterior teeth's vertex in the buccal and palatine bones. The findings imply that there are certain differences in male and female characteristics. In a multicenter investigation, these authors assessed these parameters and found that gender had an effect on the features of the maxillary bone and incisor canal. The type and diameter of the incisor canal are influenced by gender, according to other researchers<sup>(7,19)</sup> with males having noticeably larger buccal bone widths and canal lengths. Similar findings were made by Güncü and colleagues<sup>21</sup> in dentate individuals, who discovered that males had larger and longer canals than females ( $p < 0.0001$ ). Males appear to have longer and wider nasopalatine canals than females, suggesting that gender effects physical architecture. According to our research, gender also significantly affects the front maxillary zone's physical proportions. When planning surgery in the front maxillary zone, consideration must be given to the impact of the dental condition, specifically with regard to the size of the buccal bone structures. The bone crest undergoes significant vertical and horizontal reabsorption after tooth loss in the anterior maxillary area, according to studies by Sharma and colleagues<sup>14</sup> and Moya and colleagues<sup>15</sup>. Even in cases of significant reabsorption, we found substantial cortical bone in the zone anterior to the incisor canal. In patients with extensive maxillary atrophy, the aforementioned authors proposed using the bone that remains surrounding the nasopalatine nerve canal to insert implants. We do, however, stress that there was significant morphological heterogeneity in the nasopalatine canal's morphology. In 207 CT images, Mardinger and colleagues<sup>(9)</sup> evaluated the canal's diameters and found that edentulous patients had shorter canals. In a micro-CT investigation involving 56 individuals, Song and colleagues<sup>(3)</sup> observed a canal length of 11.5 mm. These authors noted that the edentulous maxilla had shorter canal lengths due to the influence of dental health on the canal's features. On the other hand, Liang and colleagues<sup>(4)</sup> were unable to corroborate the aforementioned findings despite observing differences in canal length in a CT investigation including 60 dentate and 60 edentulous patients. Similarly, due to the extremely wide interindividual variances, Asaumi and colleagues<sup>12</sup> could not find any significant differences in the morphology of the incisor canal between dentate and edentulous individuals. However, it seems that the incisor canal is active role after extraction of dentition. All above considerations, it seems that the incisor canal's NCP surrounding bone changes as a result of tooth loss. The incisor canal's diameter and the resorption activity close to the crestal ridge area appear to be altered by this action as well. Because every participant in our series loses teeth, both partially and entirely, we were able to investigate this issue. However, although some studies reveal very small reductions in bone width, others find large reductions in the alveolar crest's size right after orthodontic treatment. Since orthodontic patients were not included in the study, these results could not be verified in our series. As a conclusion, the CBCT availability to predict either premaxilla more convenient to denture rehab therapy by using removable or surgical implant therapy that clearly possible to argue that such analysis could influence different treatment outcome aspects. However, this protocol has not been studied thoroughly with a greater number of cases

and different clinical follow up protocols to see our predictive value of this study. Further studies are required to determine the influence of this study assessment protocol on the treatment outcome in terms of prognostic value time and patient-based evaluation.

**Declaration of competing interest**

The authors have no conflicts of interest relevant to this article.

**Acknowledgments**

None

## References

1. Singh GD, McNamara Jr JA, Lozanoff S. Morphometry of the midfacial complex in subjects with Class III malocclusions: Procrustes, Euclidean and cephalometric analyses 1998. *Clin Anat* 11:162–170.
2. Mohi A., Beycan K., Yalçinkaya Ş. The Vomer Bone Pattern Variations in Dentofacial Discrepancy using three-dimensional Analysis. *Clin Exp Health Sci* 2018; 8: 284-290.
3. Güncü GN, Yıldırım YD, Yılmaz HG, et al. Is there a gender difference in anatomic features of incisive canal and maxillary environmental bone? *Clin Oral Implants Res.* 2013;24:1023–1026.
4. Barteczko K, Jacob M. A re-evaluation of the premaxillary bone in humans. *Anat Embryol* 2004;207(6):417–37.
5. Mooney MP, Siegel MI. Premaxillary-maxillary suture fusion and anterior nasal tubercle morphology in the chimpanzee. *Am J Phys Anthropol* 1991.85:451–456.
6. K.M. Reich, C.D. Huber, W.R. Lippnig, C. Ulm, G. Watzek, S. Tangl, Atrophy of the residual alveolar ridge following tooth loss in an historical population, *Oral Dis.* 17 (1) (2011) 33–44, <https://doi.org/10.1111/j.1601-0825.2010.01699.x>.
7. S. Minakuchi, K. Tsuga, K. Ikebe, T. Ueda, F. Tamura, K. Nagao, J. Furuya, K. Matsuo, K. Yamamoto, et al., Oral hypofunction in the older population: position paper of the Japanese Society of Gerodontology in 2016, *Gerodontology* 35 (4) (2018) 317–324, <https://doi.org/10.1111/ger.12347>.
8. S. Salazar, Y. Hasegawa, S. Kikuchi, K. Kaneda, H. Yoneda, T. Nokubi, K. Hori, T. Ono, The impact of a newly constructed removable denture on the objective and subjective masticatory function, *J. Prosthodont. Res.* (2020), [https://doi.org/10.2186/jpr.JPR\\_D\\_20\\_00045](https://doi.org/10.2186/jpr.JPR_D_20_00045).
9. C.R. Leles, T.M.C. Oliveira, S.C. de Araujo, T.E. Nogueira, M. Schimmel, Individual factors associated with masticatory performance of complete denture wearers: a cross-sectional study, *J. Oral Rehabil.* 46 (10) (2019) 903–911, <https://doi.org/10.1111/joor.12822>.
10. T. Kosaka, M. Kida, M. Kikui, S. Hashimoto, K. Fujii, M. Yamamoto, T. Nokubi, Y. Maeda, Y. Hasegawa, et al., Factors influencing the changes in masticatory performance: the Suita study, *JDR Clin. Trans. Res.* 3 (4) (2018) 405–412, <https://doi.org/10.1177/2380084418785863>.
11. R. Sharma, A. Bhochhibhoya, B. Acharya, S.B. Rana, Clinical evaluation of residual ridge morphology of maxillary arch in relation to ageing and length of edentulism, *J. Coll. Med. Sci. - Nepal* 15 (4) (2019) 230–234, <https://doi.org/10.3126/jcmsn.v15i4.26199>.
12. T. A. o Prosthodontics, The glossary of prosthodontic terms: ninth edition, *J. Prosthet. Dent* 117 (5S) (2017) e1–e105, <https://doi.org/10.1016/j.prosdent.2016.12.001>.
13. R. Alshenaiber, C. Cowan, C. Barclay, N. Silikas, Analysis of residual ridge morphology in a group of edentulous patients seeking NHS dental implant provision—a retrospective



- observational lateral cephalometric study, *Diagnostics* 11 (12) (2021) 2348, <https://doi.org/10.3390/diagnostics11122348>.
14. M. Ryu, M. Nakamura, T. Izumisawa, K. Ishizaki, T. Ueda, K. Sakurai, Morphological investigation of residual ridge in Japanese edentulous elderly for fabrication of edentulous stock tray, *Bull. Tokyo Dent. Coll.* 60 (3) (2019) 185–192, <https://doi.org/10.2209/tdcpublish.2018-0066>.
  15. Rues S, Schmitter M, Kappel S, et al. Effect of bone quality and quantity on the primary stability of dental implants in a simulated bicortical placement. *J Clinical oral investigations* 2021; 25: 1265-1272.
  16. Kamadjaja MJK, Widjaja J and Young K. Maxillary Edentulous with Four-Implant-Supported Fixed Restorations: A Case Report. *Journal of International Dental Medical Research* 2023; 16: 1268-1271.
  17. Alhamdani F and Abdullah E. The Influence of Local Factors on Early Dental Implant Failure, 5- year Retrospective Study. *J Odontol Res* 2021; 9: 5-10.
  18. Moya-Villaescusa MJ, SánchezPérez A. Measurement of ridge alterations following tooth removal: A radiographic study in humans. *Clin Oral Implants Res.* 2010;21:237–242.
  19. Bernades-Mayordomo R, GuijarroMartínez R, Hernández-Alfaro F. Volumetric CBCT analysis of the palatine process of the anterior maxilla: A potential source for bone grafts. *Int J Oral Maxillofac Surg.* 2013;42:406–410.
  20. Mraiwa N, Jacobs R, Van Cleynenbreugel J, et al. The nasopalatine canal revisited using 2D and 3D CT imaging. *Dentomaxillofac Radiol.* 2004; 33:396–402.
  21. Pohlenz P, Blessmann M, Blake F, et al. Clinical indications and perspectives for intraoperative cone beam computed tomography in oral and maxillofacial surgery. *Oral Surg Oral Med Oral Pathol Oral Radiol Endod.* 2007;103:412–417.
  22. Tözüm TF, Güncü GN, Yildirim YD, et al. Evaluation of incisive canal characteristics related to dental implant treatment with computerized tomography: A clinical multicenter study. *J Periodontol.* 2012;83:337–343.
  23. Mardinger O, Namani-Sadan N, Chaushu G, et al. Morphologic changes of the nasopalatine canal related to dental implantation: A radiologic study in different degrees of absorbed maxillae. *J Periodontol.* 2008;79:1659–1662.
  24. Liang X, Jacobs R, Martens W, et al. Macro- and micro-anatomical, histological and computed tomography scan characterization of the nasopalatine canal. *J Clin Periodontol.* 2009;36:598–603.
  25. Chen H, van Eijnatten M, Aarab G, et al. Accuracy of MDCT and CBCT in three-dimensional evaluation of the oropharynx morphology. *Eur J Orthod.* 2018;40:58–64.